



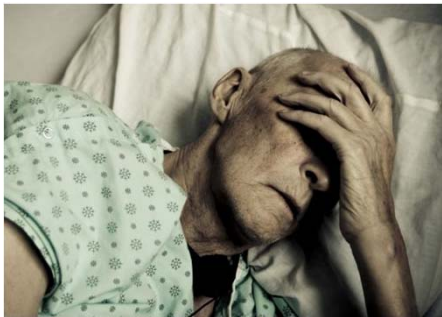The Online Dermatology Clinic

Raj Gupta, M.D., Ph.D
Chief Medical Officer

WHY WE STARTED DIRECT DERMATOLOGY?



Unnecessary Delays in Diagnosis and Treatment

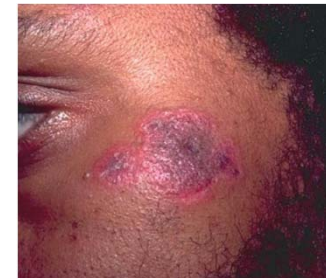
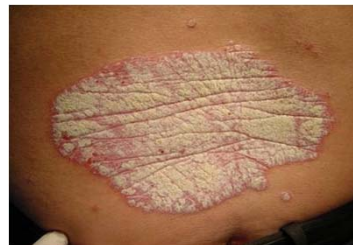
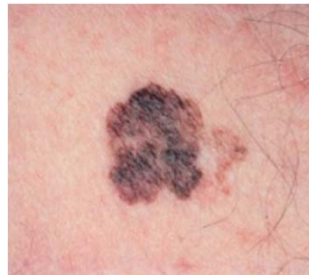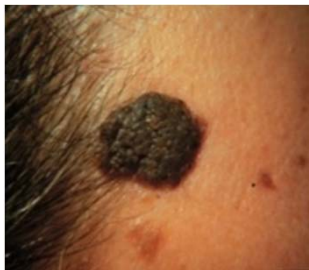Avoidable Patient Morbidity and Mortality

WHAT WE DO


Online tele-dermatology consultation service:

1. HIPAA-compliant web-based platform
2. US board-certified dermatologists

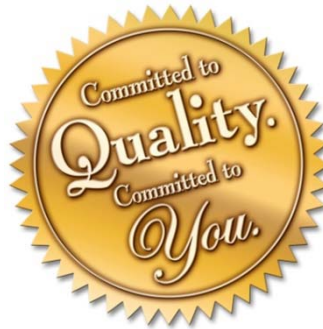

HEALTH CARE CHALLENGES

- Timely access



- High quality care









- Lower cost of care



RESOURCE FOR PRIMARY CARE

Consult dermatologists virtually from medical home

-  Wait time
-  Unnecessary ER visits
-  Unnecessary repeat PCP visits
-  In-person dermatology referrals (<6%)
-  Travel time and cost
-  Quality of care

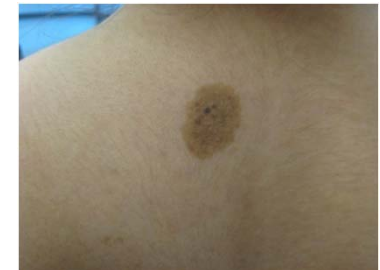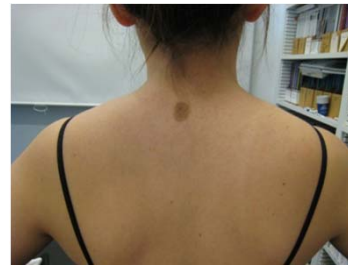HOW OUR SERVICE WORKS



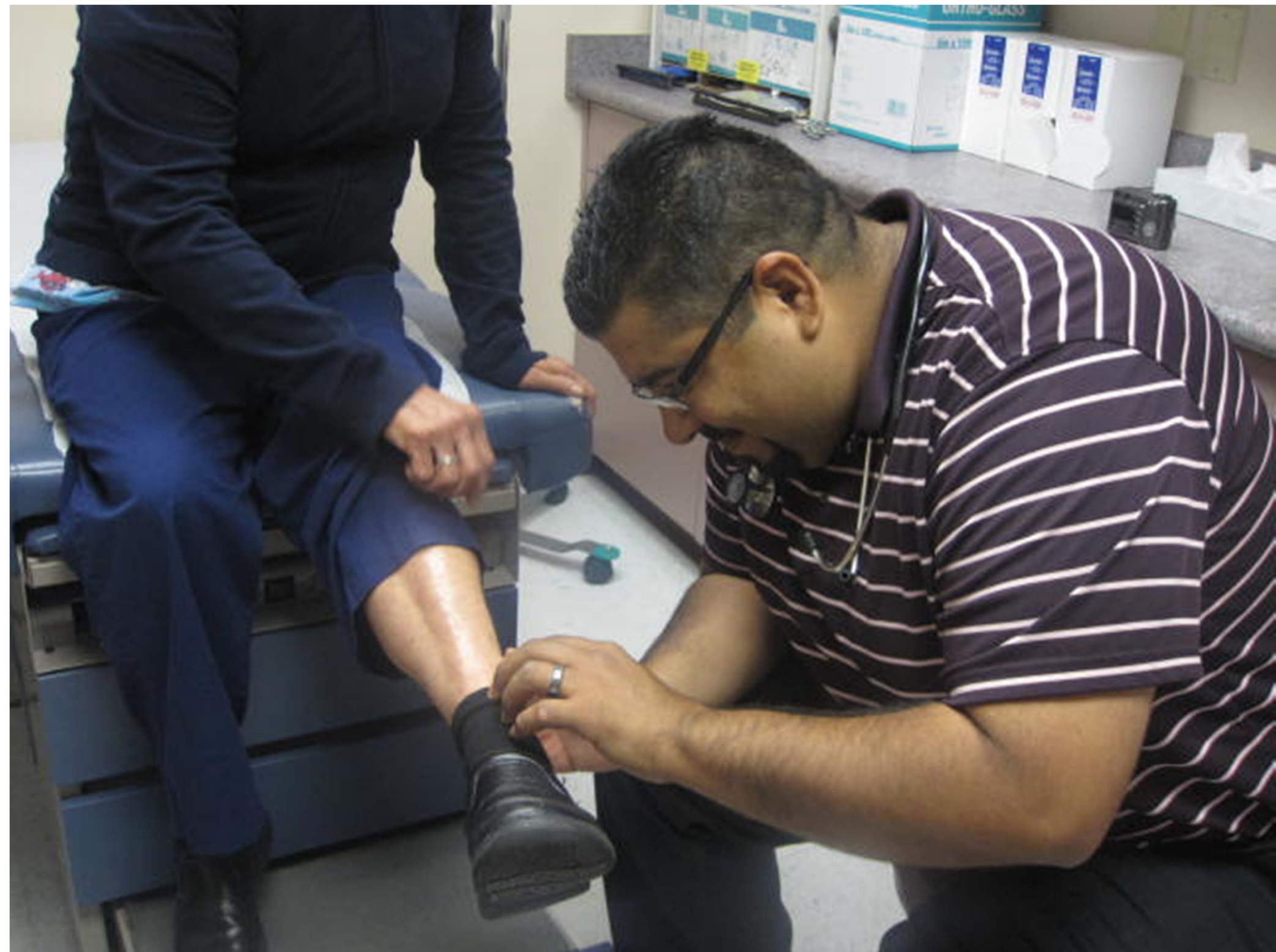Login and enter medical history




Take and upload pictures



Receive report with diagnosis and treatment







FOR REFERRING PROVIDERS

PATIENT: Jane Lee (ID#3422212)

1. PATIENT INFO

[Demographics](#)[Insurance](#)

2. MEDICAL HISTORY

Current Problem[Medications](#)[Past Medical History](#)

3. UPLOAD PHOTOS

4. CONFIRM

CURRENT PROBLEM

What is the reason for the consultation?

(Check all that apply)

- Diagnosis
 Treatment
 Second Opinion
 Follow up Visit

Enter any other reason below:

What is the nature of the skin problem?other

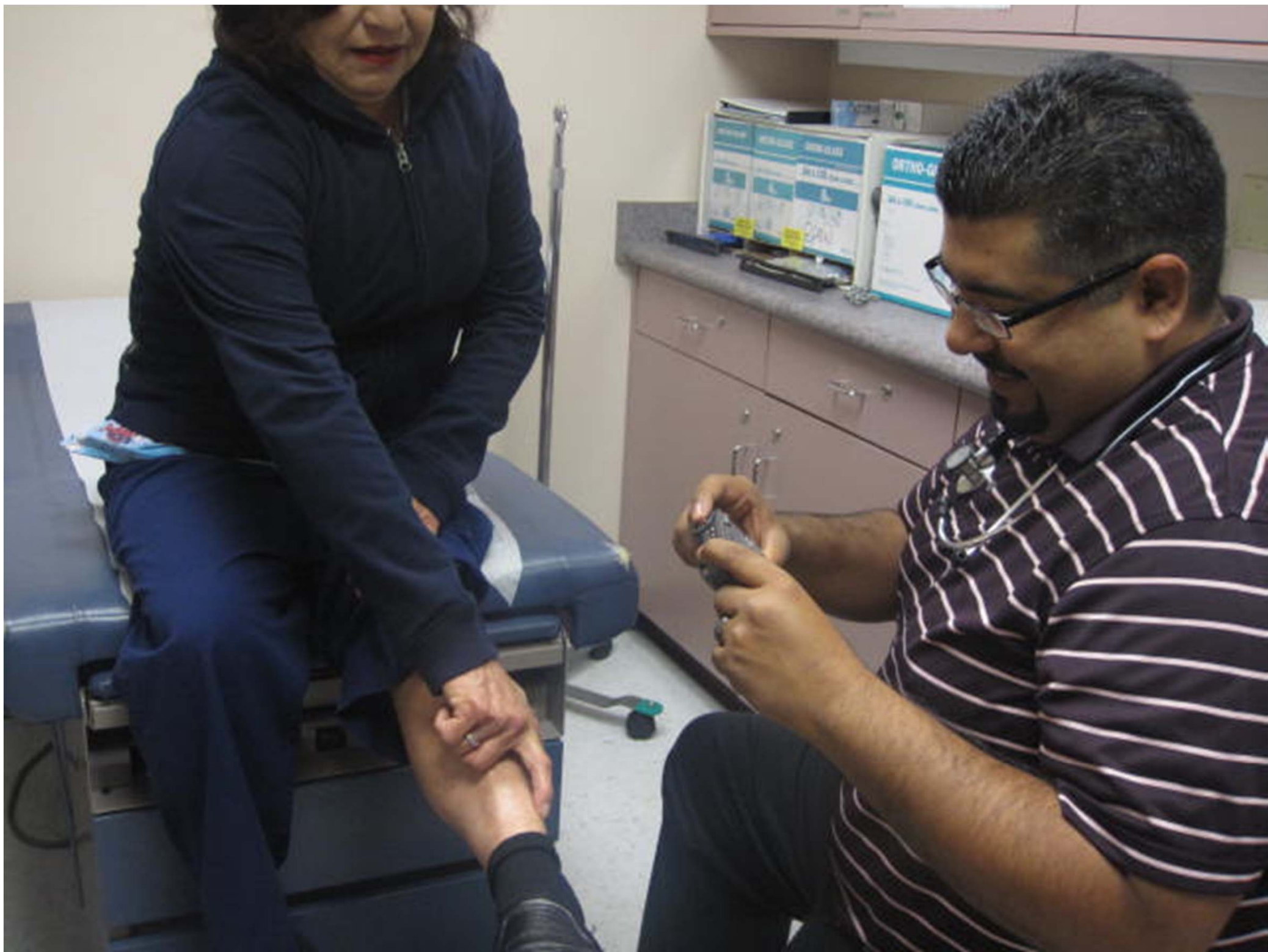
If other, please specify:

What is the provisional diagnosis:**Where is the skin problem located?**

(Please list all body locations affected, ex: "left leg" or "face, chest, and both arms")

How long has this skin problem been present?since birth **Does the problem "come and go" or is it "always present"?**

- Always Present
 Comes and Goes





FOR REFERRING PROVIDERS

PATIENT: Jane Lee (ID#3422212)

1. PATIENT INFO

[Demographics](#)

[Insurance](#)

2. MEDICAL HISTORY

[Current Problem](#)

[Medications](#)

[Past Medical History](#)

3. UPLOAD PHOTOS

4. CONFIRM

UPLOAD PHOTOS

Select an image to upload [UPLOAD](#)

Uploaded Images (Click on an image for a larger view.)



Body location



Body location



Body location

[BACK](#)

[CONTINUE](#)

[GENERAL INSTRUCTIONS](#)

[TROUBLESHOOTING GUIDE](#)

Example Images



Patient: [REDACTED] DOB: [REDACTED]
Case ID: [REDACTED] Submission date: 10/14/2010 16:50
Submitted by: [REDACTED] Clinic: [REDACTED] PA-C
Consulting Physician: Dr. [REDACTED]

Diagnosis: Atopic dermatitis - 691.8, Impetigo - 684.0

[REDACTED] is a 6-month-old Hispanic or Latino, male referred by Dr. [REDACTED] for consultation regarding:

diagnosis, treatment, of rash located on face, hands, axilla, neck.

[REDACTED] Clinic - [REDACTED] PA-C's provisional diagnosis is: atopic dermatitis.

This skin problem has been present for: 3 months, and comes and goes.

Patient complains of the following symptoms: appearance, bleeding, itching, painful.

Patient denies complaining about the following symptoms: getting larger, getting darker, burning.

Medications used for this skin problem:

Name	Drug Form	Dose or Strength	Frequency	Duration	Last Use	Response
Tramcinolone	ointment	0.1%	BID	2 months	still using	Improved slightly
elidel	cream	1%	BID	1 month	still using	Improved slightly

This skin problem has not been previously biopsied.

Review of systems:

Fever:	no	Chills:	no
Fatigue:	no	Joint pain or stiffness:	no
Mouth sores:	no	Shortness of breath:	no

Other medications currently taken by the patient: None

Current medical problems: None

Drug allergies:

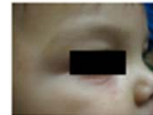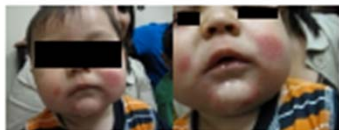Penicillin:	no	Cephalosporin:	no
Sulfis:	no	Tetracycline:	no
Aspirin:	no	Other:	no

History of skin problem:

	Patient	Family
Skin cancer:	no	no
Melanoma:	no	no
Eczema:	no	no
Psoriasis:	no	no

Physical exam:

rash located on face, hands, axilla, neck.



Ill defined eryth plaques with scale bilateral cheeks, perioral region, periorcular region (R>L) and L dorsal hand. Some crusting visible in involved areas on face. Lichenification of involved areas on L dorsal hand

Diagnosis	ICD9
Atopic dermatitis	691.8
Impetigo	684.0

Assessment and Recommendations:

Based on the information provided:

1. Atopic Dermatitis, with moderate to severe involvement on face.
2. Probable secondary impetigo

Recommendations:

- 1) Take bacterial swab for culture and sensitivity of involved areas on face
- 2) Cephaloslin 25 mg/kg/day divided tid X 2 weeks
- 3) Hydrocortisone ointment 2.5% ointment bid daily to affected areas on face
- 4) Continue with Tramcinolone ointment 0.1% bid to affected areas on hands
- 5) Discuss in detail routine skin care measures with parents for long term management.

NOTE: Proper skin lubrication is the mainstay of therapy because atopic dermatitis wease and wease. Wipe weather often exacerbates atopic

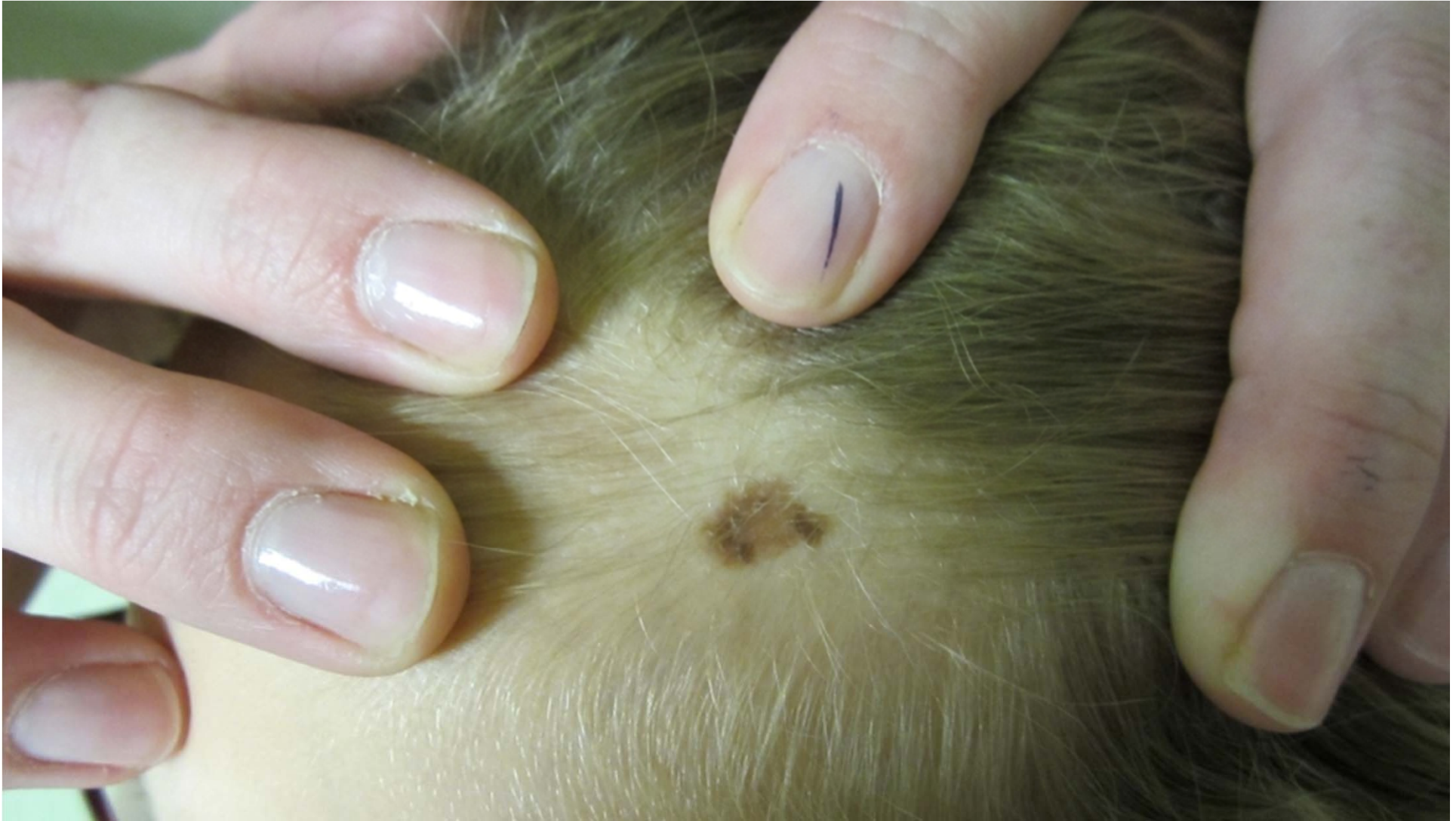- 1) Cut the child's nails as short as possible to prevent more destructive excoriation.
- 2) Get some Aveno Oatmeal bath additive and use warm but not hot water for bathing if a bath is available.
- 3) Adding 2 teaspoons of household bleach (e.g., Clorox) per gallon of bath water will help reduce incidence of Staphylococcus infections which occur more frequently in atopic skin because 90% of atopic patients have Staph colonization on their skin compared to non-atopic individuals (20%).
- 4) Use Cetaphil Cleanser for bathing or showering or Dove Soap if Cetaphil is not available.
- 5) After bathing or showering, before bedtime and as needed during the day in between applications of a topical corticosteroid (as indicated above), apply small amounts of Vaseline Petroleum or Aquaphor to all dry skin that the patient tends to scratch (NOTE: a pea-sized amount of the ointment is enough to cover an area the size of the entire forehead - it shouldn't feel greasy after massaging into skin - if it does too much has been applied).
- 6) Use light cotton pajamas for sleep and hand mittens if the baby tends to scratch a lot.

There are no additional questions.

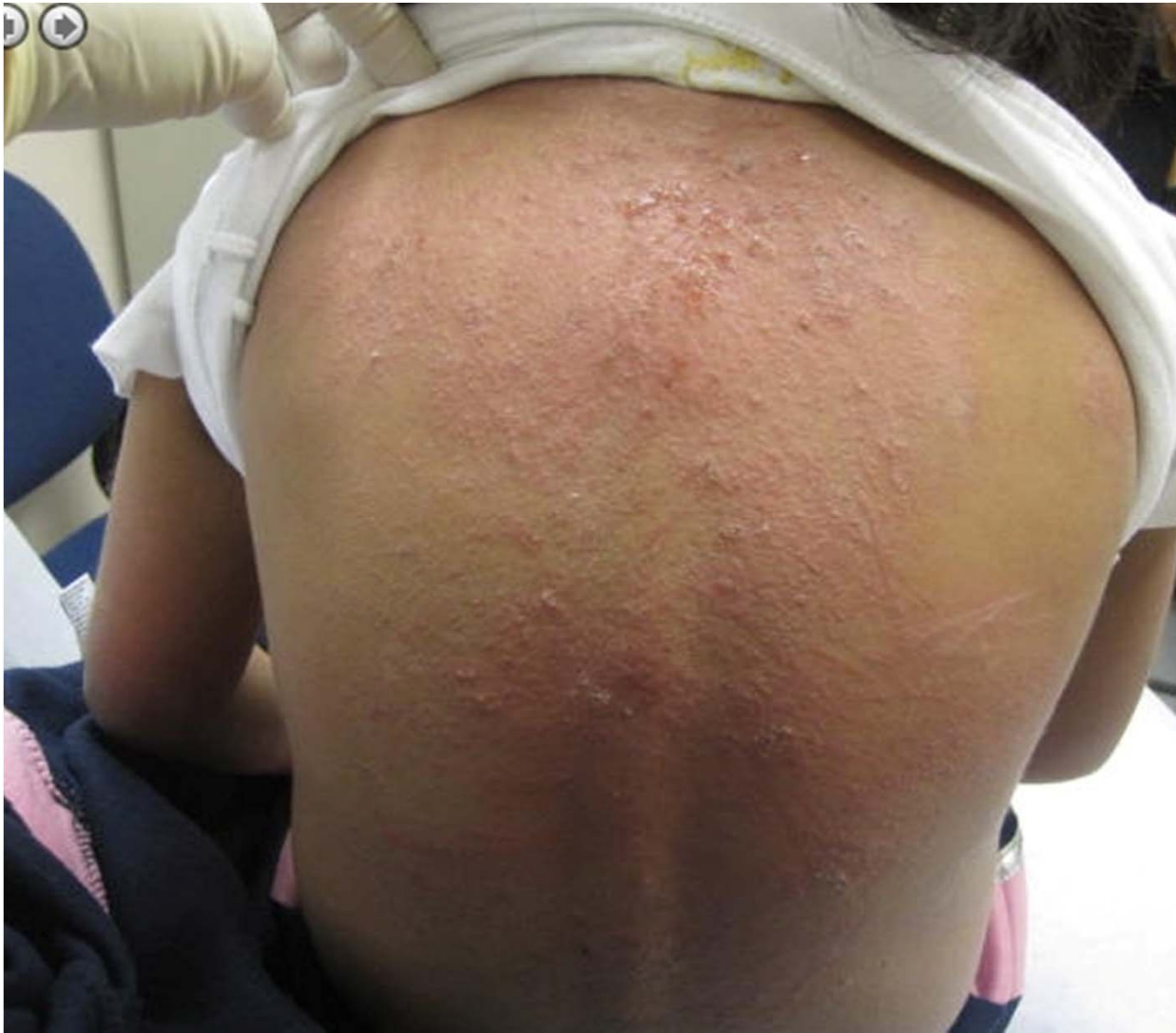Follow-up recommendation:

Follow up with repeat teledermatology consultation in 1 month to monitor progress.

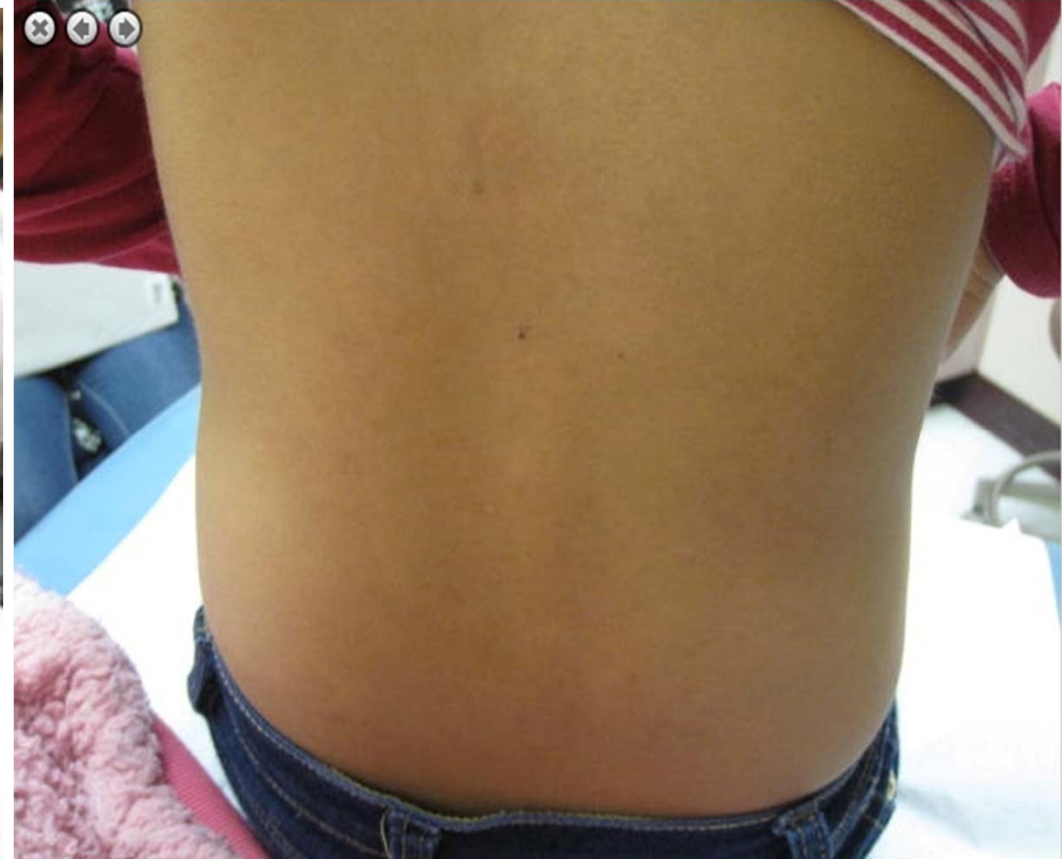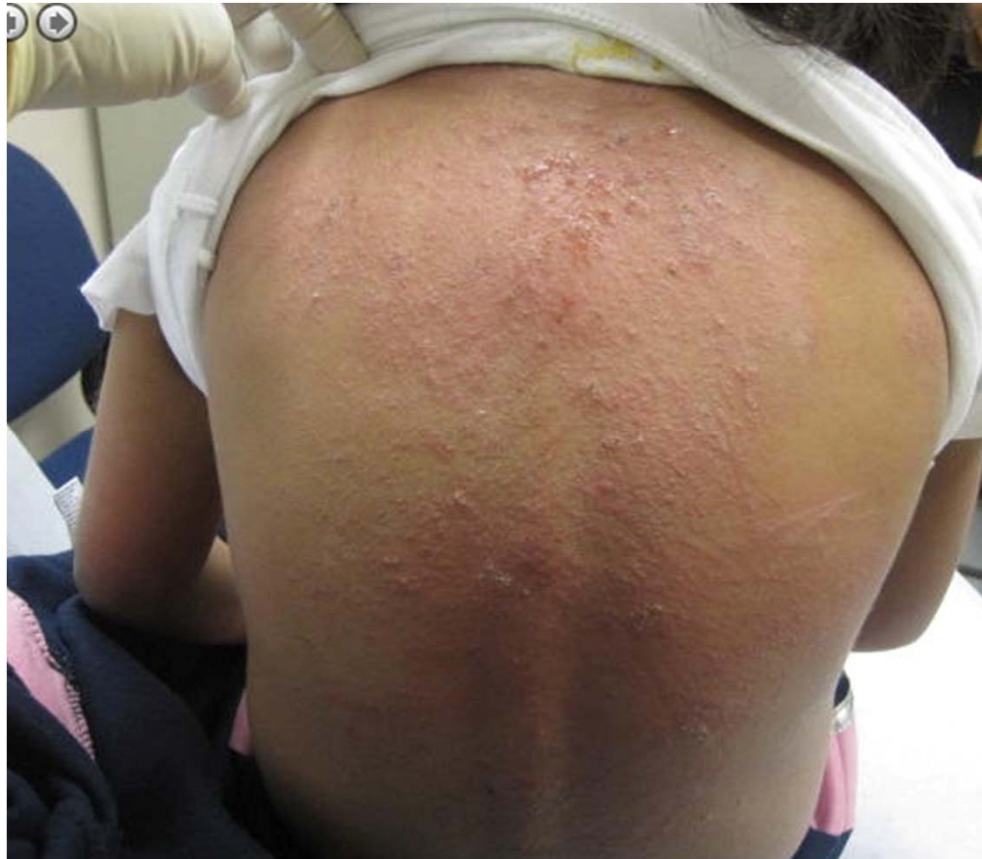Electronically signed by: Rajnish Gupta, MD - Direct Dermatology on 10/18/2010 1:08



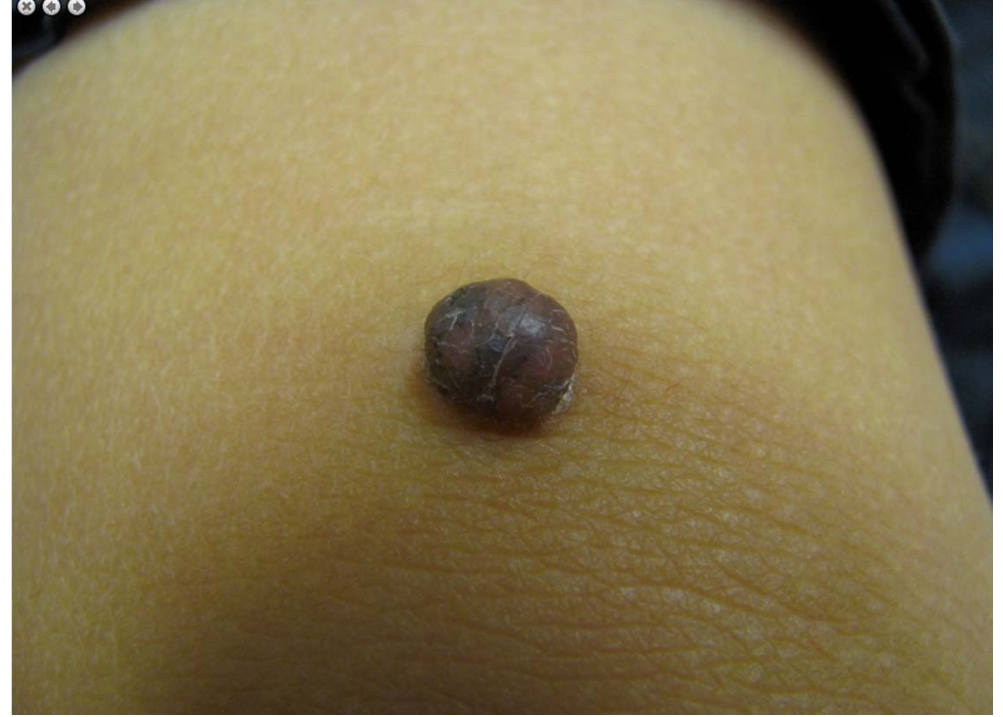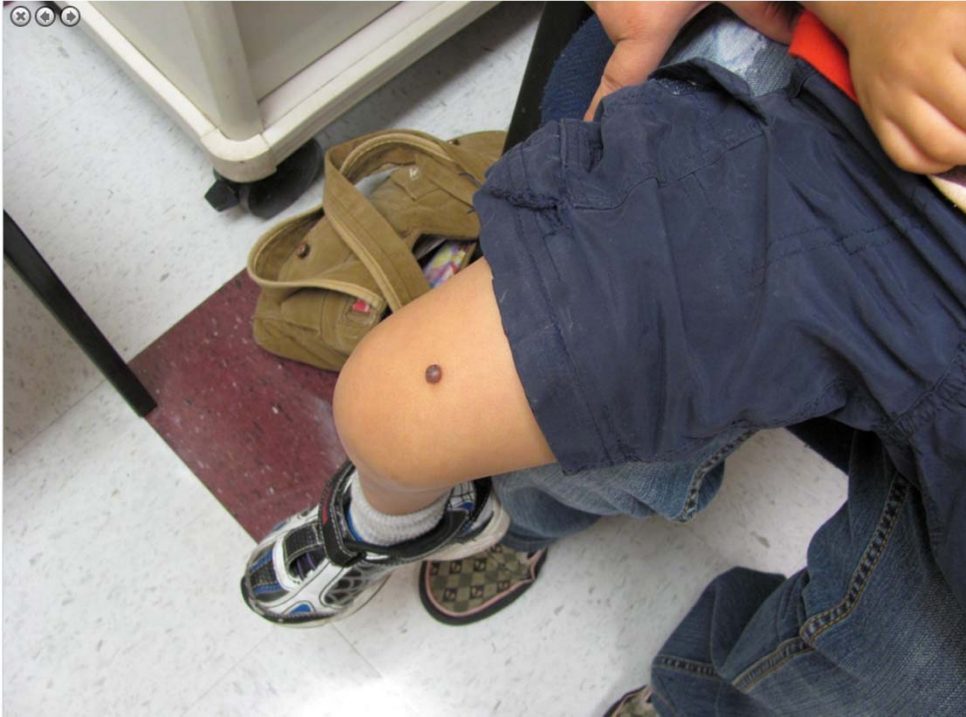150 days (3600 hours) vs. 1/3 day (8 hours)



6 months (>180 days): 8 PCP visits with 10 prescriptions



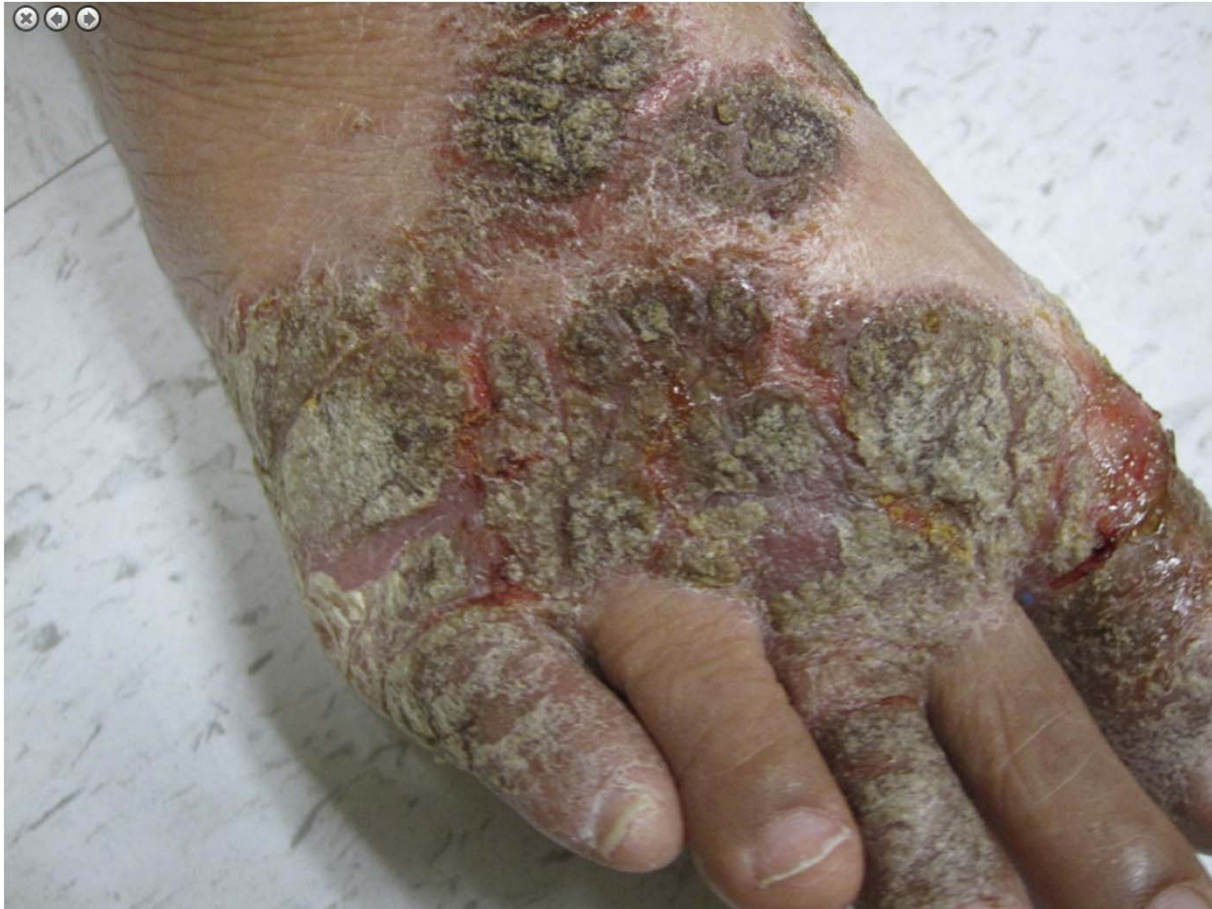1 day: Diagnosis made by Direct Dermatology
2 weeks after follow up: Complete resolution



Community dermatologist wait: **150 days**
DirectDerm saw patient in: **1 day**

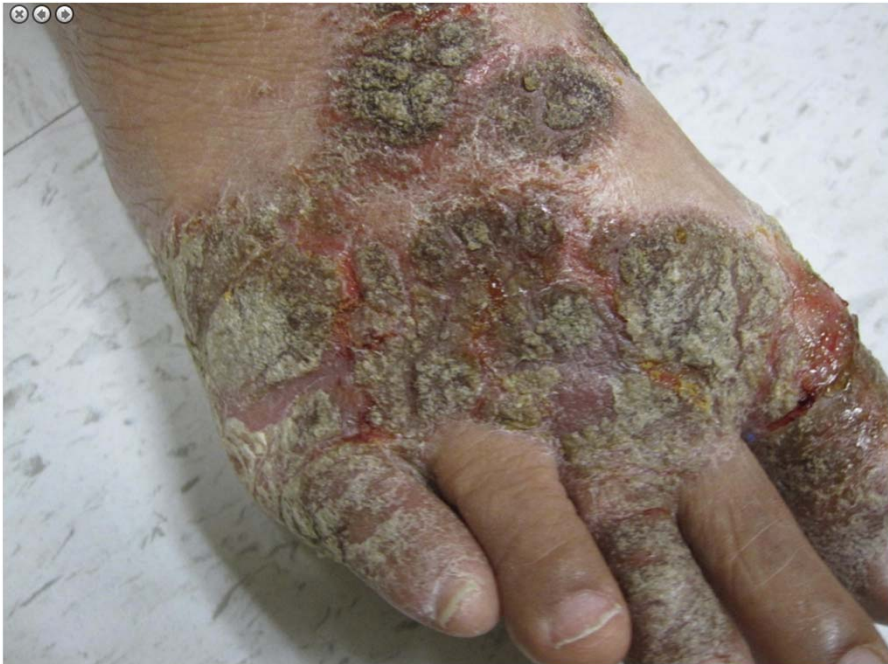Diagnosis: Spitzoid Melanoma

Excision and sentinel lymph node biopsy done at UCSF in < 2 mo

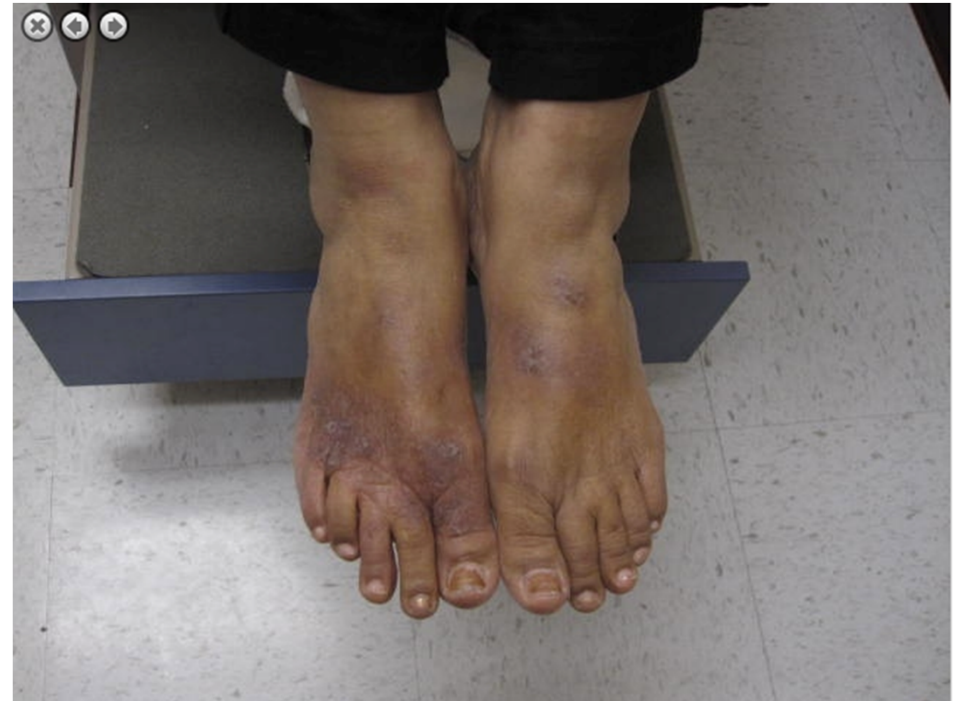

3 PCP visits for same problem spanning **over 3 months**
3 prescriptions given and no improvement

Before DirectDerm



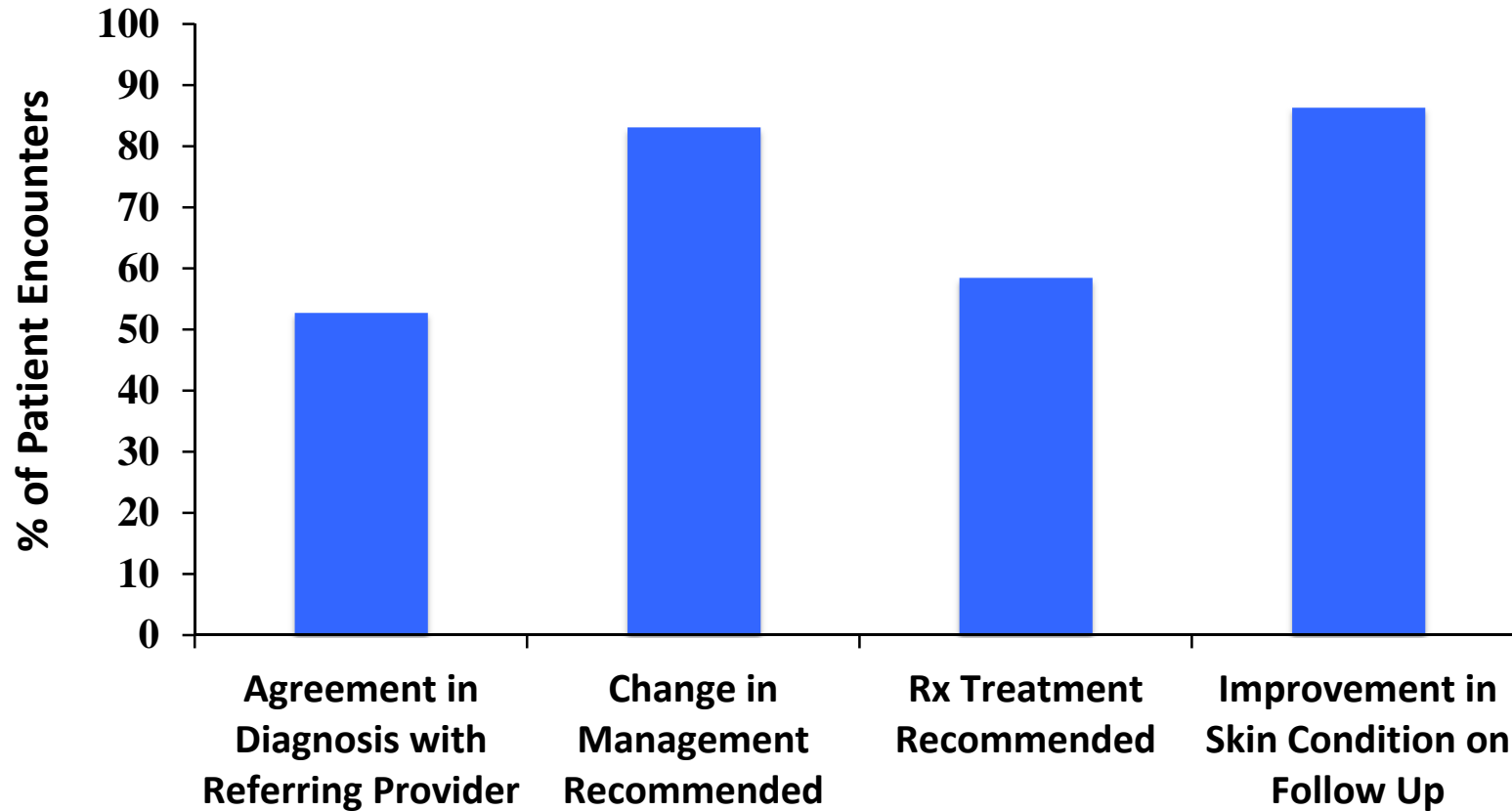
2 months after DirectDerm



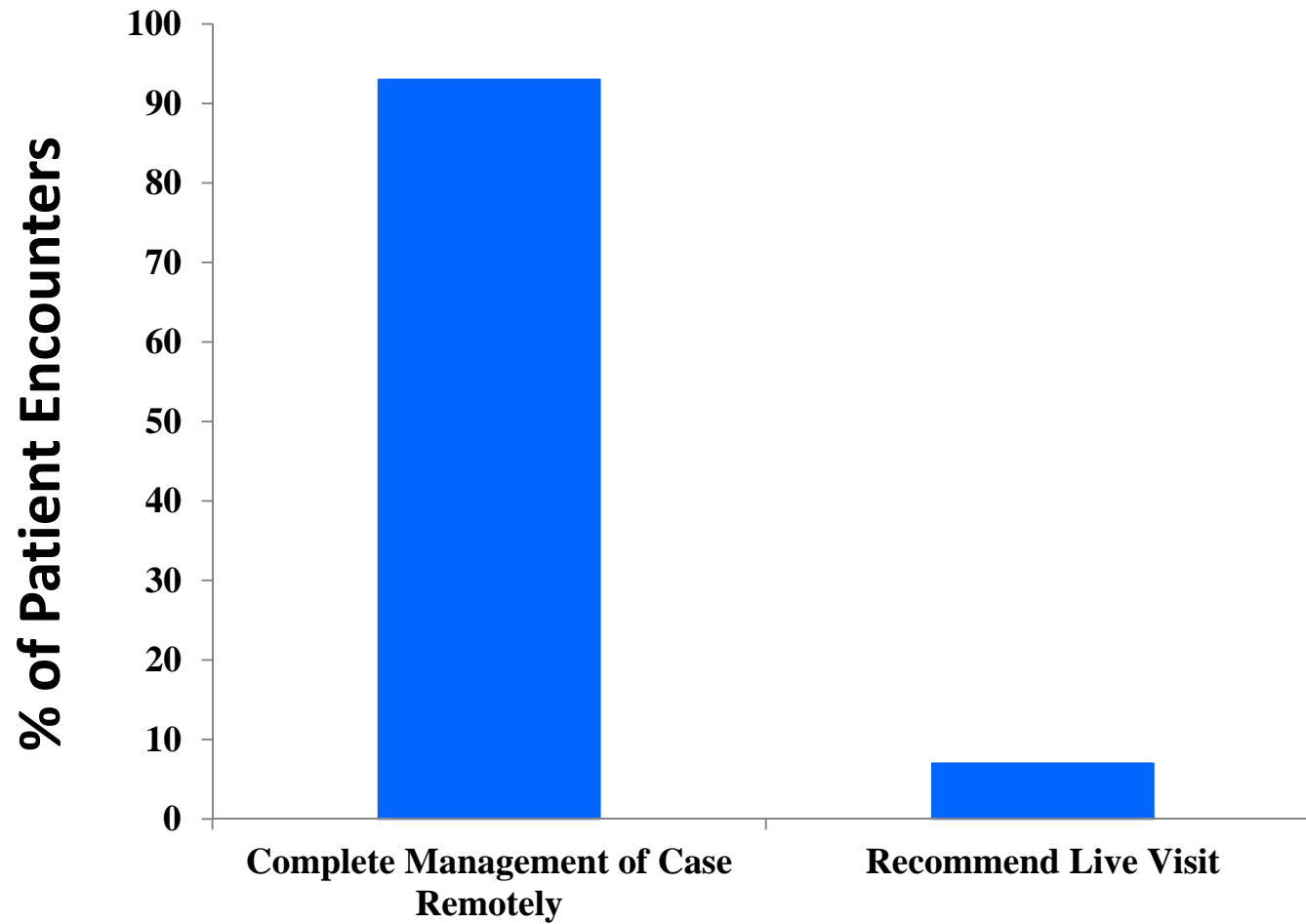
DirectDerm saw patient in: **1 day**

Diagnosis: Psoriasiform drug eruption

2 months follow-up: Significant improvement



Tracking the Effectiveness of Our Service



CONTACT

Raj Gupta, MD

650-704-6993

rgupta@directderm.com

www.directdermatology.com